

An eSheath, left IJ approach to implantation of a Micra leadless pacemaker in a 2-year-old, 10.9 kg burn victim

Daniel Cortez ^{1*}, Amr El-Bokl², Jonathan Dayan¹, Jay Yeh¹, Gary Raff¹, and Frank Ing¹

¹Department of Pediatric Cardiology, Director of Pediatric Electrophysiology, UC Davis Medical Center, Sacramento, CA, USA; and ²University of Minnesota, Minneapolis, MN, USA

*Corresponding author. E-mail address: dancortez@ucdavis.edu

Introduction

While the small size of a leadless pacemaker presents benefits such as lack of lead distortion with growth without pacemaker pocket complications, wider adoption of this technology has been limited.^{1,2} We present a leadless pacemaker implantation case in a 10.9 kg paediatric patient with haemodynamically significant complete heart block and circumferential burn wounds/grafting.

Case

A 2-year-old female was transferred emergently from rural Mexico after sustaining third-degree circumferential thoracic/abdominal burns. She was noted to have irreversible third-degree heart block with junctional escape rate in the 50–60 bpm range with signs/symptoms of low cardiac output including altered mental status/intermittent hypotension. She was started on isoproterenol at 0.02 µg/kg/min with improvement. The patient had extensive skin grafting/harvesting. Post-operatively, multiple slow attempts to wean isoproterenol over weeks resulted in bradycardia/lethargy/poor perfusion/mentation. Interdisciplinary discussions were held with paediatric cardiology/electrophysiology/cardiothoracic surgery/burn surgery/critical-care/anaesthesia teams with a transcatheter leadless pacemaker approach preferred over any incisional implantation, including of epicardial leads given degree/location of grafting/burns.

Using the Seldinger technique, a 6 Fr sheath was placed in the 1.2 cm diameter left IJ (vs. smaller 0.8 cm right IJ). Serial dilation was carried out by 2-Fr size until a 16-Fr, 36 cm long eSheath/dilator (Edwards Lifesciences, Irvine, CA, USA) was advanced over a guidewire into the mid-right atrium. After heparinization, the 23-F Micra dilator (Medtronic, Minneapolis, MN, USA) was then used to expand the inner diameter of the eSheath in preparation for implantation of the Micra. The 55.7 cm Micra sheath (Medtronic) was cut/shortened to 20 cm to allow for sufficient length of the Micra catheter. Using the Micra dilator, the shortened Micra sheath was introduced through the 16-Fr eSheath valve to allow passage of the Micra into the eSheath. Subsequently, the Micra catheter was passed through the eSheath to the mid-right atrium, and the eSheath was retracted back to the innominate vein. The Micra was advanced across the tricuspid valve, under echocardiographic/fluoroscopic guidance, to an apical-septal position. Due to lack of septal engagement, a second deployment was needed for proper implantation. The catheter/sheath was removed, and a figure-of-8 stitch was placed for haemostasis.

Pacing threshold was 0.38 V at 0.24 ms, R-wave of 3.5 mV, and impedance 610 ohms, programmed VDD 70 to 115 bpm, mode switch VVIR at 115 bpm with upper sensor rate of 170 bpm.

Three tines were engaged. No complications occurred (Panels A and B).

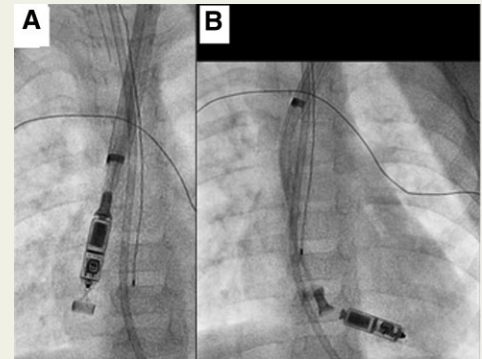
Four-month follow-up demonstrated threshold of 0.5 V at 0.24 ms, R-wave of 9.0 mV, and impedance of 605 ohms. A3 and A4 programming were used as the atrial accelerometer vector with 43% A-sense, V-paced rhythm.

Discussion

We demonstrate feasibility of Micra placement in a 10.9 kg patient through a 16 Fr eSheath, which helped decrease consistent tension/stretch of the small patient's veins once the Micra passed through it. Right or left IJ placement with the Micra sheath, without a surgical cut-down, has been demonstrated to be safe in larger patients.^{1,3} Echocardiographic guidance was helpful to ensure unhindered tricuspid valve function and right ventricular device position.

Conclusion

A modified technique using the 16 Fr eSheath permitted safe/effective leadless pacing in a 10.9 kg patient via left IJ access without cut-down.



References

1. Siddeek H, Jimenez E, Ambrose M, Braunlin E, Steinberger J, Bass J, et al. Pediatric Micra leadless pacemaker implantation via the internal jugular and femoral vein: a single-center, US experience. *Future Cardiol* 2021;**17**:1116–22.
2. Breatnach CR, Dunne L, Al-Alawi K, Oslizlok P, Kenny D, Walsh KP. Leadless Micra pacemaker use in the pediatric population: device implantation and short-term outcomes. *Pediatr Cardiol* 2020;**41**:683–6.
3. Surti AK, Ambrose M, Cortez D. First description of a successful leadless pacemaker implantation via the left internal jugular vein (in a 20 kg patient). *J Electrocardiol* 2020;**f60**: 1–2.